

Summarised from *Journal of Clinical Periodontology*, Volume 49, issue 9 (September 2022), 889-898

Editor: Andreas Stavropoulos, chair, EFP scientific affairs committee

Rapporteurs:

Nargiz Aliyeva, Matteo Corana, Veronica Del Lupo, Federica Romano, Giacomo Baima, with Dr Giulia Maria Mariani and Prof. Mario Aimetti

Affiliation:

Postgraduate programme in periodontology, C.I.R. Dental School, Turin, Italy

study

Do growth factors enhance alveolar ridge preservation in extraction sockets?

Authors:

Xuzhu Wang, Melissa R. Fok, George Pelekos, Lijian Jin, Maurizio S. Tonetti

Background

Autologous blood-derived growth factors (ABD-GF) and the second-generation platelet concentrate leucocyte- and platelet-rich fibrin (L-PRF), have received considerable clinical attention in recent years. The assumption behind this growing interest is that the local application of ABD-GF or L-PRF provides higher concentrations of bioactive molecules locally, and this may improve the wound-healing process.

However, to date little is known about the *in vivo* concentrations of growth factors in extraction sockets during natural healing or following L-PRF application.

Aim

To compare the local release pattern of growth factors, early wound healing, and changes in alveolar-ridge dimensions in naturally healing extraction sockets versus those receiving L-PRF for alveolar-ridge preservation.

Materials & methods

- Study design: intra-individual randomised controlled clinical trial with a five-month follow-up.
- Population and treatment: systemically healthy, non-smoking subjects (18-70 years old) who needed extraction of two hopeless non-molar teeth because of caries, root resorption, or orthodontics. Teeth with periodontal involvement, periapical lesion, or acute abscess were excluded. The experimental teeth were randomly allocated to test (L-PRF application) or control treatment (spontaneous healing).
- Study outcomes:
 - Change in horizontal alveolar ridge dimension 1mm below the alveolar crest at five months (primary outcome), assessed by 3D intraoral digital scans.
 - Changes in growth-factor kinetics and cytokine concentration in wound fluid collected with sterile paper strips at six, 24, 72, and 168 hours.
 - Early wound healing by the modified wound healing index (WHI).
 - changes in linear-ridge profile, comparing baseline and five-month 3D intraoral digital scans after superimposition.
 - Buccal volume changes calculated after converting the superimposed STL files into solid volumes.
 - Vertical and horizontal hard-tissue dimension changes on superimposed CBCT images after five months of healing.
 - The possibility of placing a prosthetically guided implant (PGI) of a standard size (8mm length, 3.3mm diameter) or the need for augmentation.
- Statistical analysis included: area under the curve (AUC) analysis, repeated measures linear mixed model, and paired t-test to estimate the total amounts of biomarkers released during the study and the differences between and within groups; McNemar-Bowker test to compare groups in the proportion with ability for standard PGI placement.

Figure 1: Representative case illustrating early healing and alveolar changes. Occlusal view of post-extraction socket healing process in a control site (A) and in an L-PRF site (B).

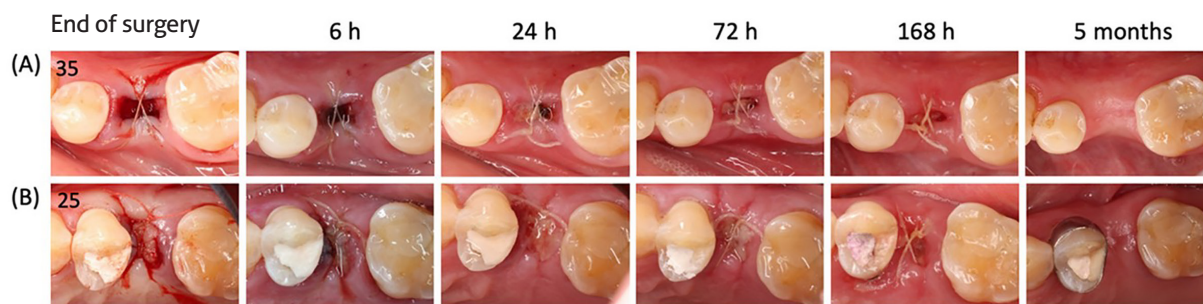
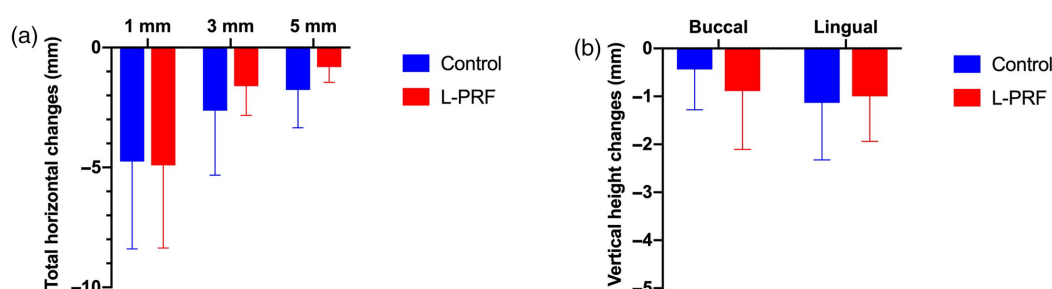


Figure 2: a) Horizontal linear changes in alveolar bone width between baseline and five-month follow-up, 1, 3, and 5mm below the lingual bone crest. (b) Vertical hard-tissue changes at buccal and lingual aspects between baseline and five-month follow-up.



Results

- Eighteen patients (nine women) were included; in most cases, the extracted teeth were maxillary premolars.
- Higher concentration of growth factors in wound fluid following local application of L-PRF than in control sites. The differences were statistically significant for platelet-derived growth factor-AA (PDGF-AA), transforming growth factor- β 1 (TGF- β 1), and vascular endothelial growth factor (VEGF).
- No intergroup differences in modified WHI at six, 24, 72, and 168 hours (see figure 1).
- Significant contractions of the ridge profile at all extraction sites between baseline and five-month follow-up, without significant differences between groups ($p > .05$).
- Radiographic alveolar bone resorption in both groups, with changes in vertical bone height and horizontal bone thickness being comparable between the groups ($p > .05$) (see figure 2).
- Concerning the possibility of placing a PGI, there were no significant differences in the proportions of standard placement, simultaneous guided bone regeneration, or staged placement between the two groups ($p > .05$).

Limitations

- Small sample size.
- Only subjects without any risk factors for impaired wound healing.
- Only non-molar teeth.
- Lack of comparison in patient-reported outcomes because of the intra-individual study design.
- Possible errors in superimposing CBCT images.
- No bone-replacement graft was used to support blood-clot stability, which could be beneficial in alveolar-ridge preservation.

Conclusions & impact

- L-PRF did not alter the growth-factor profile, but it did provide higher local concentration in wound fluid; however, this did not translate into enhanced soft-tissue healing or any clinical benefit.
- The healing pattern did not differ between groups.
- Horizontal and vertical alveolar-ridge resorption occurred in both groups, resulting in a similar need for a second bone-augmentation procedure or a staged procedure to enable PGI placement.
- More studies are needed to clarify the biological activity of the elevated growth-factor concentration in wound fluid when L-PRF is applied and its possible impact on alveolar-ridge preservation.



JCP Digest 105 is a summary of 'Increased local concentrations of growth factors from leucocyte- and platelet-rich fibrin do not translate into improved alveolar ridge preservation: An intra-individual mechanistic randomized controlled trial.' *J Clin Periodontol.* 49(9):889-898. DOI: 10.1111/jcpe.13688



<https://www.onlinelibrary.wiley.com/doi/10.1111/jcpe.13688>



Access through EFP members' page log-in: <http://efp.org/members/jcp.php>