

**Rapporteurs:**

Javier Calatrava and Antonio Nobili,  
with Prof. Mariano Sanz and Prof. David Herrera

**Affiliation:**

EFP-accredited programme in periodontology at the University  
Complutense of Madrid, Spain

**study**

# Does a collagen matrix add dimensional stability in guided bone regeneration?

**Authors:**

Goran I. Benic, Stefan P. Bienz, Young Woo Song, Jae-Kook Cha, Christoph H.F. Hämmerle, Ui-Won Jung, Ronald E. Jung

## Background

In cases where there is insufficient bone availability to place implants, guided bone regeneration (GBR) simultaneous with implant placement is commonly used. It is usually performed with particulated grafting materials and resorbable membranes, as explained by the systematic review published in 2019 by Thoma et al. However, both this review and other studies showed how the combination of these materials for successful regeneration was sometimes not predictable and it was not adequate in the case of non-contained bone defects, mainly because of their lack of dimensional stability.

As a result, different materials have been developed to increase dimensional stability, such as the soft-type block, which consists of a mixture of particles of bone substitutes in a collagen matrix. This combination was developed for alveolar ridge preservation (ARP) because of its increased ability to maintain the augmented space and the ridge contours, as was shown in the results of two *in vitro* studies (Mir-Mari et al., 2016, 2017).

However, there is still not enough evidence from *in vivo* pre-clinical and clinical studies, especially regarding the long-term results when using these materials.

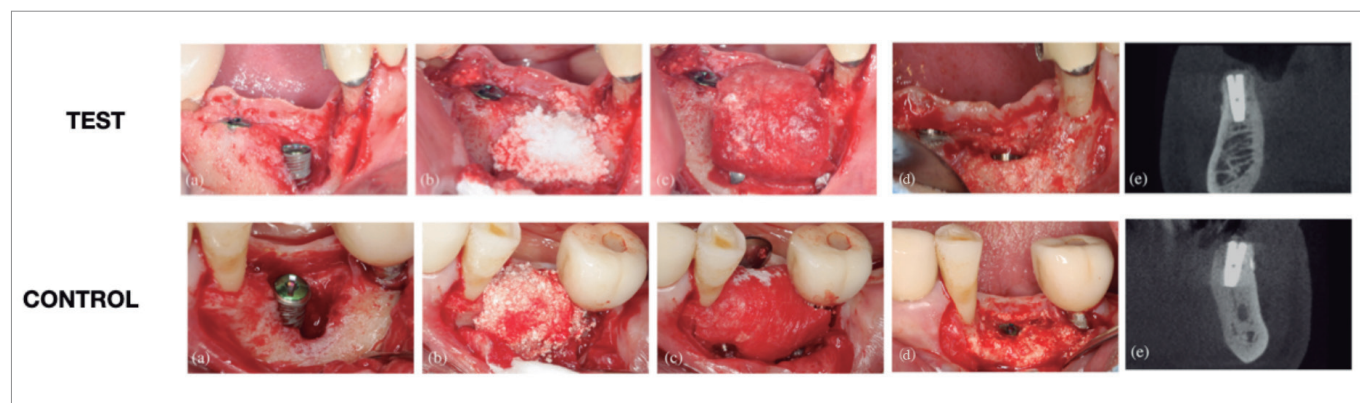
## Aim

The aim was to compare the hard-tissue dimensions and dimensional stability after guided bone regeneration of peri-implant defects, using either a soft-type block-bone substitute, in which the bone substitute was incorporated into a collagen matrix, or a particulated bone substitute.

## Materials & methods

- This prospective randomised clinical trial included 40 patients in need of at least one dental implant and simultaneous bone augmentation of peri-implant defects, with a follow-up of six months. Conventional inclusion and exclusion criteria for implant therapy were applied, and heavy smokers were excluded.
- Forty patients were randomised into two parallel treatment groups. Patients in the control group received a particulate synthetic biphasic calcium phosphate (BCP), comprising 60% hydroxyapatite and 40% beta tricalcium phosphate (HA/TCP), whereas those in the test group received a soft-type block bone in which the same synthetic BCP was embedded in a collagen matrix (CM) to improve its dimensional stability.
- Implants were placed at least two months after tooth extraction, leaving peri-implant bone defects that were filled and over-augmented with the material during the surgery. Bone dehiscences were classified in contained and non-contained defects, and their apicocoronal dimension was measured on the buccal implant surface. Local antiseptics and systemic antibiotics were prescribed during the healing period.
- Re-entry surgeries were performed six months after implant placement, and the residual presence of bone dehiscences was measured, along with other clinical parameters.
- Cone beam computed tomography (CBCT) scans were performed at baseline, immediately after implant placement, and after six months, and assessed by a blinded investigator. The horizontal dimension of the augmented bone at the implant shoulder was evaluated and considered as the primary outcome variable for sample calculation.
- Other radiographic variables such as the vertical and diagonal dimension of augmented bone were also evaluated at the various time points.

**Figure:** Complete clinical sequence of each treatment modality with full defect resolution



Baseline situation after implant placement (a), guided bone regeneration with the selected bone graft (b), collagen membrane stabilised (c), complete defect resolution at re-entry surgery (d), and CBCT six months after implant placement (e).

## Results

- Thirty-five subjects were finally included in the six-month analysis (17 in the test group and 18 in the control group).
- With regards to soft-tissue dehiscences, only one was found in each group.
- Horizontal hard-tissue dimensional changes, measured by CBCT, showed mean augmentation values of 1.15mm (test) and 0.93mm (control), with no statistically significant differences.
- When clinically measuring apicocoronal hard tissue changes at the re-entry surgery, 58.8% of the test sites and the 55.6% of the control sites, showed a complete vertical defect fill. When assessed by CBCT, higher percentages of complete vertical defect fill were observed (82.4% for the test group and 88.9% for the control group).
- Combining both groups, 14 contained and 21 non-contained defects were included. At six months, only two of the 14 contained defects (7.1%) did not achieve complete vertical fill (both in the control group); while 13 out of 21 (61.9%) non-contained defects did not achieve complete vertical bone fill, with similar results in both groups – 58.3% (test) and 66.7% (control).
- In both type of defects, there was a reduction in the horizontal dimension of the augmented hard tissue, comparing post-operative and six-month measurements.
- The average time after tooth extraction was longer for non-contained defects (7.5 months) compared with contained defects (3.0 months).

## Limitations

- Sample: no information about the smoking habits of patients (only that heavy smokers were excluded); use of the term “active periodontal disease”, which does not follow the current classification.
- Surgical procedure: wide time range after tooth extraction, membrane stabilisation could have been improved, and a high exposure rate after two and four weeks in both groups.
- Main radiographical outcome variable might not be adequate, as clinical measurements show less resolution and are not ideal because three different CBCTs were needed within six months.
- Unclear if the lack of statistically significant differences in the results resulted from the sample size calculation, which was merely empirical, based on a superiority trial design. Only 35 patients attended the short-term follow-up.

## Conclusions & impact

- Immediately after wound closure, GBR with a soft-type BCP and collagen block combined with a CM and fixation pins lead to superior dimensions of augmented hard tissue compared to a particulate graft plus CM.
- However, at re-entry, six months later, this dimensional stability favouring the test group was not observed, and no differences were found regarding augmented hard-tissue dimensions.
- The use of either a soft-type collagen-containing block or particulate bone grafts in combination with a buccally tacked CM is not a predictable alternative in reaching complete resolution of non-contained peri-implant bone defects.
- Neither GBR with a BCP bone graft in a particulate presentation nor supported with a collagen matrix creating a soft-type block seem to be the ideal treatment option when treating non-contained bone defects simultaneous to implant placement.



JCP Digest 101, published in May 2022, is a summary ‘Randomized controlled clinical trial comparing guided bone regeneration of peri-implant defects with soft-type block versus particulate bone substitutes: Six-month results of hard tissue changes.’ *J Clin Periodontol.* 49(5):480-495. DOI: 10.1111/jcpe.13606



<https://www.onlinelibrary.wiley.com/doi/10.1111/jcpe.13606>



Access through EFP members' page log-in: <http://efp.org/members/jcp.php>